Evaluation of Women With Atypical Glandular Cells on Cervical Cytology

Melissa K. Frey, MD; Divya Gupta, MD

The finding of atypical glandular cells on cervical cytology can present a diagnostic challenge for ObGyns.

Atypical glandular cells (AGC) are an uncommon finding, occurring in less than 1% of screening Pap tests. However, considerable research has been directed at the significance of this result, because of the high risk for underlying malignancy of the genital tract in women with this finding. Studies have reported the risk for premalignant and malignant conditions from 17% to 59%.[1-7]

The 2001 Bethesda System to report abnormalities of cervical cytology significantly changed the classifications for AGC on a Pap test.[8] The term atypical glandular cells of undetermined significance (AGUS) was eliminated to avoid confusion with a similar term, atypical squamous cells of undetermined significance (ASC-US). AGC results are subclassified as follows:

- AGC, endocervical or endometrial or not otherwise specified (NOS)
- AGC, favor neoplasia (AGC-FN) (endocervical or NOS).

Multimodality testing is required to evaluate patients with AGC Pap results, including colposcopy, human papillomavirus (HPV) testing, endometrial sampling, and cervical cone biopsy.

Significance of AGC on Cervical Cytology Testing

The differential diagnosis for AGC includes benign, premalignant, and malignant conditions. The most common benign lesions associated with AGC are chronic endocervicitis, endometriosis, squamous metaplasia, tubal metaplasia, microglandular hyperplasia, unintentional sampling of the lower uterine segment, pregnancy, thermal injury, previous cone biopsy, radiation, endosalpingiosis, and cervical polyps.[4,9] The premalignant and malignant conditions associated with AGC include squamous cervical intraepithelial neoplasia (CIN), adenocarcinoma in situ (AIS) of the cervix, complex endometrial hyperplasia, and malignancies of the lower genital tract (uterus, cervix, vagina), upper genital tract (ovary, fallopian tube), and rarely, abdominal or distant nonreproductive organs.[4,7]

AGC is often difficult to classify histologically. While liquid-based preparation (LBP) cytology has increased sensitivity for detecting squamous cervical lesions as compared to the conventional manual Pap screening test, the data regarding LBP as a diagnostic tool for AGC are conflicting.[10-14] There is a high degree of interobserver variability in the interpretation of AGC specimens by cytologists, with some studies suggesting this inconsistency to be as high as 45%.[15] Glandular cells detected on Pap testing can

Melissa K. Frey, MD, is Resident in Obstetrics and Gynecology; and **Divya Gupta, MD,** is Assistant Professor, Department of Obstetrics and Gynecology, Division of Gynecologic Oncology, Weill Cornell Medical College, New York Presbyterian Hospital, New York, NY.

TABLE. Summary of Studies That Include Patients With AGUS or AGC Cytology[1,3-7]

Study	Burja et al, 19993	Geier et al, 20016	Koonings et al, 20014	Meath et al, 20021	Schnatz et al, 20067	Zhao et al, 20095
# Pap specimens reviewed	18,198	8,221	353,644	N/A	2,389,206	247,131
AGUS/AGC Pap results N (%)	377 (2.1)	490 (6.0)	308 (0.1)	855	6,829 (0.3)	1,021 (0.4)
AGUS/AGC included in study* N	64	353	281	855	3,890	662
CIN-I N (%)	14 (21.9)	49 (13.9)	N/A	N/A	331 (8.5)	109 (16.5)
CIN-II/III N (%)	21 (32.8)	58 (16.4)	51 (18.1)	187 (21.9)**	432 (11.1)	33 (5.0)
AIS N (%)	2 (3.1)	7 (2.0)	10 (3.6)	18 (2.1)	113 (2.9)	16 (2.4)
Cervical carcinoma, N (%)	1 (1.6)	2 (0.6)	14 (5.0)	17 (2.0)	59 (1.5)	6 (0.9)
Endometrial hyperplasia N (%)	0 (0.0)	8 (2.3)	0 (0.0)	25 (2.9)	54 (1.4)	20 (3.0)
Endometrial carcinoma N (%)	0 (0.0)	1 (0.3)	11 (3.9)	47 (5.5)	117 (3.0)	34 (5.1)
Other malignancy N (%)	0 (0.0)	0 (0.0)	6 (2.1)	10 (1.2)	27 (0.7)	4 (0.6)

Abbreviations: AGC, atypical glandular cells; AGUS, atypical glandular cells of unknown significance; AIS, adenocarcinoma in situ; CIN, cervical intraepithelial neoplasia; N/A, not available.

* Patients included in study for whom follow-up results were available.

** Low- and high-grade squamous intraepithelial lesions not reported separately.

originate from multiple sites, including the endocervix, endometrium, fallopian tube, or peritoneal cavity following transuterine migration.[9] In addition, there is a lack of well-defined cytomorphologic criteria for diagnosis.

Reported rates of the association of AGC cytology with premalignant and malignant conditions vary widely, ranging from 17% to 59%.[1-7] A summary of these studies is presented in the Table. A meta-analysis identified 3,890 women with AGUS or AGC cervical cytology from 24 studies on whom follow-up was available. Among these women, 20.6% had clinically significant lesions: high-grade CIN (11.1%), cervical AIS (2.9%), endometrial hyperplasia (1.4%), and malignancy (5.2%).[7]

Another large retrospective review identified 662 women with AGC and found that 17.1% of patients had clinically significant precancerous or malignant lesions: 7.5% had CIN-II/III or AIS, 3.0% had endometrial hyperplasia, and 6.6% had an underlying malignancy (cervical, endometrial, or ovarian).[5] This study also showed that while women with AGC cytology younger than 40 are more likely to have a cervical malignancy, those older than 50 more commonly have endometrial carcinoma.

It is important to note that the primary sites of cancer diagnosed in women with AGC are not limited to the lower genital tract. There are reports of AGC cytology arising from malignancies of the upper reproductive tract, including ovary (5.4%-10.9% of all diagnosed malignancies) and

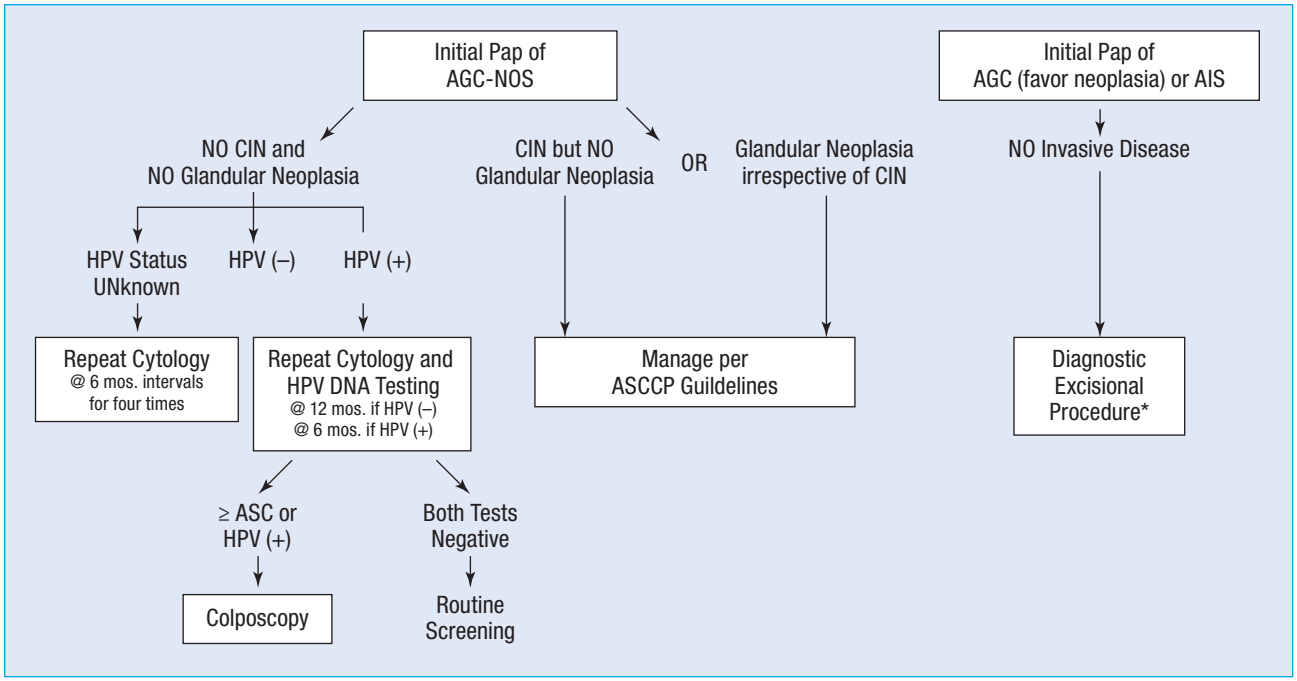

FIGURE. Subsequent management of women with atypical glandular cells.

fallopian tube (1%). Malignancies of other pelvic or distant organs are also associated with AGC cytology: bladder (3.2%), colon (3.2%), and breast (3.2%).[4,5,15]

Based on data from the largest published meta-analysis, endometrial adenocarcinoma is still the most commonly diagnosed malignancy in women with AGC (57.6% of all diagnosed malignancies), followed by cervical adenocarcinoma (23.6%), cervical squamous cell carcinoma (5.4%), ovarian cancer (5.4%), and fallopian tube cancer (1.0%).[7] One of the challenges in managing these conditions is that the neoplastic lesion is often located in an area that is difficult to sample, such as high endocervical canal, endometrium, adnexa, and occasionally extragenital sites.[9] There is a concern that these lesions may not be diagnosed by conventional office examinations such as colposcopy, endocervical curettage, or endometrial biopsy.

In addition to cervical cytology, other patient-related factors can be used to stratify the risk for malignancy during evaluation of AGC cytology. These include the AGC subclassification (AGC-NOS or AGC-FN), presence of concomitant ASC-US on Pap screening, patient age, and HPV status. A recently published meta-analysis found that women with AGC had a 20.6% risk for clinically significant pathology.[9] When stratified by subclassification, AGC-NOS was associated with a 13% risk and AGC-FN with a 48% risk, indicating that the finding of AGC-FN predicts an increased risk for clinically significant underlying pathology.

The same study also evaluated women with concurrent AGC and ASC-US and found their risk for underlying disease to be 44%. These women have a significantly higher likelihood for a premalignant or malignant lesion of the cervix versus another organ.[5] Patient age has an adjunct diagnostic value when evaluating AGC Pap tests. CIN-II and CIN-III are the most common significant histologic findings in women younger than 35 years. However, patients older than 35 years with AGC more commonly have endometrial neoplasia.[4,5,16]

Concurrent testing for high-risk HPV with AGC cytology is helpful. Studies have shown that only 24% to 45% of AGC cytology test positive for high-risk HPV DNA.[17-19] However, patients with AGC cytology who also test positive for high-risk HPV DNA have an increased

risk for cervical pathology. One study demonstrated that 96% of women with biopsy-confirmed CIN-II/III and 85% with AIS or invasive cervical adenocarcinoma had AGC cytology and were positive for high-risk HPV DNA.[17] Women with AGC cytology who are HPV negative have a higher risk for endometrial or upper genital tract carcinoma.[19]

Testing for high-risk HPV is especially useful as an adjunctive screen in patients with AGC-NOS cytology or those patients in whom the initial evaluation is negative for cervical or endometrial pathology. Studies have shown that patients with AGC-NOS Pap test results who are also HPV negative have a low risk for cervical or endometrial neoplasia; 80% to 90% of patients in this category do not have lower genital tract disease.[17] In these patients, persistent AGC cytology should prompt an investigation of upper genital tract or abdominal or peritoneal disease. HPV testing does not appear to predict the presence of endometrial or extrauterine disease in patients with AGC.

Evaluation and Follow-Up of AGC Cervical Cytology

Multimodality testing is required to evaluate patients with AGC Pap test results. Initial evaluation of all patients with AGC cytology, including adolescents, should be to perform an evaluation of the cervix with testing for high-risk HPV subtypes and colposcopic-directed biopsies with endocervical curettage. Endometrial sampling with office endometrial biopsy is recommended for all women 35 or older or for those with risk factors for endometrial neoplasia.

Coding for Evaluation of Women With Atypical Glandular Cells on Cervical Cytology

Philip N. Eskew Jr, MD

The ICD-9 diagnosis code for this finding is:

795.00 Abnormal glandular Papanicolaou smear of cervix
Atypical endocervical cells NOS
Atypical endometrial cells NOS
Atypical cervical glandular cells NOS

The CPT codes for the multimodality testing:

57454 Colposcopy of the cervix including the upper/adjacent vagina;
with biopsy(s) of the cervix and endocervical curettage
+58110 Endometrial sampling (biopsy) performed in conjunction with colposcopy
(List separately in addition to code for primary procedure)
58100 Endometrial sampling (biopsy) with or without endocervical sampling (biopsy), without cervical dilation, any method (separate procedure)
57520 Conization of cervix, with or without fulguration, with or without dilation and curettage, with or without repair, cold knife or laser
87621 Papillomavirus, human, amplified probe technique

Once you have a finding of the abnormal Pap smear, use the 795.00 diagnosis code for the next visit when you will be performing one of the above procedures. If a tissue diagnosis is obtained, use that code (622 series or 233.1 cervical neoplasia) for any therapeutic procedure. For subsequent visits to confirm normal cervical Pap results following a previous abnormal Pap, use V72.32.

V72.32 Encounter for Papanicolaou cervical smear to confirm findings of recent normal smear following initial abnormal smear

The E & M code used when performing a follow-up Pap smear is usually 99212. If the patient has questions, the correct code could be based on time. If it is based on time, document the questions and summarize your responses in the medical record.

99212 Physicians typically spend 10 minutes face-to-face with the patient and/or family.
99213 Physicians typically spend 15 minutes face-to-face with the patient and/or family.
99214 Physicians typically spend 25 minutes face-to-face with the patient and/or family.

When counseling and/or coordination of care dominates (more than 50%) the physician/patient and/or family encounter (face-to-face time in the office), then time shall be considered the key or controlling factor to qualify for a particular level of E & M services.

Philip N. Eskew Jr, MD, is past member, *Current Procedural Terminology (CPT)* Editorial Panel; past member, *CPT* Advisory Committee; past chair, ACOG Coding and Nomenclature Committee; and instructor, *CPT* coding and documentation courses and seminars.

Women who have atypical endometrial cells on Pap testing can initially be evaluated with endocervical and endometrial sampling. If this testing is negative, then colposcopic-directed biopsies and high-risk HPV testing should be done. For patients with AGC with AIS or atypical endocervical cells favoring neoplasia or adenocarcinoma, initial colposcopic-directed biopsies, endocervical curettage, and endometrial sampling should be performed.

In all patients (except AGC-NOS and HPV negative), if the initial biopsies are nondiagnostic or negative, then a diagnostic excision procedure should be performed because of the high risk for underlying premalignant or malignant conditions. A cold-knife cone is recommended instead of a loop electrode excision procedure because of the ability to evaluate for invasive disease and margin status. If the results of the excision procedure are negative and the initial endometrial biopsy was also normal, this should prompt evaluation of malignancy in the upper genital tract (fallopian tubes, ovary, peritoneum) or from other pelvic and distant organs. This evaluation could include pelvic ultrasound, computed tomography of the abdomen and pelvis, colonoscopy, and mammography. Findings of neoplastic disease should prompt a referral to a gynecologic or surgical oncologist, as appropriate.

If the initial evaluation is negative for any premalignant or malignant lesion in a patient with AGC-NOS cytology, she can be triaged to repeat cytology and HPV testing depending on the initial HPV results (Figure). If it was positive for high-risk HPV, then repeat cytology in 6 months; if negative for high-risk HPV, then repeat cytology in 12 months. If the repeat cytology is normal, then the patient can be triaged to routine cervical cancer screening. If the repeat cytology shows anything worse than ASC-US, or persistent AGC (high-risk HPV positive or negative), then repeat office evaluation with colposcopic-directed biopsies, endocervical curettage, and endometrial sampling is recommended. If this is all negative, then a diagnostic excision procedure is done to evaluate for a lesion in the endocervical canal.

Evaluation of AGC in pregnancy is similar to that in nonpregnant patients except that endometrial sampling and endocervical curettage are contraindicated because of the risk of disrupting the pregnancy. In pregnant patients, invasive cancer is treated with the same guidelines as in nonpregnant patients in consultation with high-risk ObGyn oncologists. Preinvasive conditions, such as AIS, CIN-II, or CIN-III, can be treated in the postpartum period.

Conclusion

AGC presents a challenging dichotomy to ObGyns. It has a low incidence on Pap testing. However, patients with this finding have a high incidence of an underlying malignant or premalignant process. It is important to thoroughly evaluate women with the diagnosis of AGC on routine cervical cytology. The American Society for Colposcopy and Cervical Pathology and ACOG have published recommended guidelines for the management of women with AGC cervical cytology.[20,21] The guidelines are available online at: www.g-o-c.org/uploads/asccp_2006_consensus_guidelines.pdf.

The authors report no actual or potential conflicts of interest in relation to this article.

References

1. Meath AJ, Carley ME, Wilson TO. Atypical glandular cells of undetermined significance. Review of final histologic diagnoses. *J Reprod Med.* 2002;47(4):249-252.
2. Kennedy AW, Salmieri SS, Wirth SL, Biscotti CV, Tuason LJ, Travarca MJ. Results of the clinical evaluation of atypical glandular cells of undetermined significance (AGCUS) detected on cervical cytology screening. *Gynecol Oncol.* 1996;63(1):14-18.
3. Burja IT, Thompson SK, Sawyer WL Jr, Shurbaji MS. Atypical glandular cells of undetermined significance on cervical smears. A study with cytohistologic correlation. *Acta Cytol.* 1999;43(3):351-356.
4. Koonings PP, Price JH. Evaluation of atypical glandular cells of undetermined significance: is age important? *Am J Obstet Gynecol.* 2001;184(7):1457-1459.
5. Zhao C, Austin RM, Pan J, et al. Clinical significance of atypical glandular cells in conventional Pap smears in a large, high-risk U.S. West Coast minority population. *Acta Cytol.* 2009;53(2):153-159.

6. Geier CS, Wilson M, Creasman W. Clinical evaluation of atypical glandular cells of undetermined significance. *Am J Obstet Gynecol.* 2001;184(2):64-69.
7. Schnatz PF, Guile M, O'Sullivan DM, Sorosky JI. Clinical significance of atypical glandular cells on cervical cytology. *Obstet Gynecol.* 2006;107(3):701-708.
8. Solomon D, Davey D, Kurman R, et al; Forum Group Members; Bethesda 2001 Workshop. The 2001 Bethesda System: terminology for reporting results of cervical cytology. *JAMA.* 2002;287(16):2114-2119.
9. Schnatz PF, Sharpless KE, O'Sullivan DM. Use of human papillomavirus testing in the management of atypical glandular cells. *J Low Genit Tract Dis.* 2009;13(2):94-101.
10. Biscotti CV, Dawson AE, Dziura B, et al. Assisted primary screening using the automated ThinPrep Imaging System. *Am J Clin Pathol.* 2005;123(2):281-287.
11. Hecht JL, Sheets EE, Lee KR. Atypical glandular cells of undetermined significance in conventional cervical/vaginal smears and thin-layer preparations. *Cancer.* 2002;96(1):1-4.
12. Bai H, Sung CJ, Steinhoff MM. ThinPrep Pap Test promotes detection of glandular lesions of the endocervix. *Diagn Cytopathol.* 2000;23(1):19-22.
13. Sireci AN, Crapanzano JP, Mansukhani M, et al. Atypical glandular cells (AGC): ThinPrep Imaging System (TIS), manual screening (MS), and correlation with Hybrid Capture 2 (HC2) HPV DNA testing. *Diagn Cytopathol.* 2010;38(10):705-709.
14. Wang N, Emancipator SN, Rose P, Rodriguez M, Abdul-Karim FW. Histologic follow-up of atypical endocervical cells. Liquid-based, thin-layer preparation vs. conventional Pap smear. *Acta Cytol.* 2002;46(3):453-457.
15. Levine L, Lucci JA 3rd, Dinh TV. Atypical glandular cells: new Bethesda Terminology and Management Guidelines. *Obstet Gynecol Surv.* 2003;58(6):399-406.
16. Sharpless KE, Schnatz PF, Mandavilli S, Greene JF, Sorosky JI. Dysplasia associated with atypical glandular cells on cervical cytology. *Obstet Gynecol.* 2005;105(3):494-500.
17. Derchain SF, Rabelo-Santos SH, Sarian LO, et al. Human papillomavirus DNA detection and histological findings in women referred for atypical glandular cells or adenocarcinoma in situ in their Pap smears. *Gynecol Oncol.* 2004;95(3):618-623.
18. Rabelo-Santos SH, Derchain SF, Villa LL, et al. Human papillomavirus-specific genotypes in cervical lesions of women referred for smears with atypical glandular cells or adenocarcinoma in situ. *Int J Gynecol Pathol.* 2009;28(3):272-278.
19. Zhao C, Florea A, Austin RM. Clinical utility of adjunctive high-risk human papillomavirus DNA testing in women with Papanicolaou test findings of atypical glandular cells. *Arch Pathol Lab Med.* 2010;134(1):103-108.
20. Wright TC Jr, Massad LS, Dunton CJ, Spitzer M, Wilkinson EJ, Solomon D; 2006 ASCCP-Sponsored Consensus Conference. 2006 consensus guidelines for the management of women with abnormal cervical screening tests. *J Low Genit Tract Dis.* 2007;11(4):201-222.
21. American College of Obstetricians-Gynecologists. ACOG Committee Opinion. Evaluation and management of abnormal cervical cytology and histology in the adolescent. Number 330, April 2006. *Obstet Gynecol.* 2006;107(4):963-968.

The Female Patient
Monthly Online Audio Cast

The Role of Soy Isoflavones in Menopausal Health

Scan the QR image with your smartphone's barcode reader to listen to Dr Wolf Utian discuss the results of the NAMS report on the role of soy isoflavones in menopausal health.

To access this audio cast you can also text AUDIO to 25827

Or go to **www.myfpmobile.com/audio/web0911**

STAY CONNECTED

THE FEMALE PATIENT

Don't have a smartphone? No Problem!

The Audio Casts will also be available online at www.femalepatient.com.